

# Lingual Frenectomy in a 60-days-old Infant: Case Report Using Diode Laser

Amanda Saladine Nascimento<sup>1</sup>, Erika Regina Stocco Di Francesco<sup>2</sup>, Ricardo Scarparo Navarro<sup>3</sup>, Alessandra Baptista<sup>3</sup> and Irineu Gregnanin Pedron<sup>4\*</sup>

<sup>1</sup>Undergraduate student, Universidade Brasil, São Paulo, Brazil.

<sup>2</sup>DDS, Private practice, São Paulo, Brazil

<sup>3</sup>Professor, Department of Postgraduate in Bioengineering (Laser in Dentistry), Universidade Brasil, São Paulo, Brazil.

<sup>4</sup>Professor, Department of Periodontology, Implantology, Stomatology, Laser and Therapeutics, Universidade Brasil, São Paulo, Brazil

\*Corresponding Author: Irineu Gregnanin Pedron, Professor, Department of Periodontology, Implantology, Stomatology and Laser in Dentistry, Universidade Brasil, São Paulo, Brazil, Tel: +55 11 2944-4067

Received: April 28, 2022 Published: May 16, 2022

## Abstract

The lingual frenum, even at a young age, can hinder physiological processes such as chewing, swallowing and phonation. Lingual frenectomy is the surgical treatment for the removal of the lingual frenum when it is very strong and persistent. The conventional surgical removal may present several trans- and postoperative complications, such as the high risk of infection, hemorrhage and technical difficulties, especially in younger children. Surgical laser has been widely employed in several dental specialties. In this perspective, the use of the diode laser presents several benefits in soft tissue surgeries. The purpose of this article is to present a case of lingual frenectomy using the diode laser in a 60-days-old infant. The procedure was indicated and requested by the pediatrician, to favour milking during breastfeeding.

**Keywords:** Lingual Frenum; Frenectomy; Laser Surgery; Pediatric Dentistry; Infant.

## Introduction

The lingual frenum is strongly associated with the etiology of ankyloglossia, and may cause several complications, most of them functional. Among the main complications are difficulties in chewing, swallowing and phonation. These alterations may develop social disturbances<sup>1-6</sup>.

Lingual frenectomy is the surgical treatment for the removal of the lingual frenum when it is very strong and persistent. The removal of the lingual frenum is frequently recommended by the pediatrician or speech therapist to favour lingual movement and adequate functional activities. When performed early, it may prevent or minimize the complications resulting from the presence of the lingual frenum. Additionally, orthodontic and speech therapy may be necessary to help restore the normal functional activities of the stomatognathic system<sup>1-6</sup>.

The conventional surgical removal may present several trans- and postoperative complications, such as the high risk of infection, hemorrhage and technical difficulties, especially in younger children. For the management and treatment of children, the use of faster, simple, precise and less invasive techniques is always the best option. The use of surgical laser in frenectomy presents several advantages. Absence of bleeding, facilitating the visualization field of the surgical site, reduction of the amount of local anesthetics and decontamination of the surgical wound are some of them<sup>1,4-9</sup>. The use of laser in soft tissue dental surgeries was approved by the FDA (Food and Drug Administration) in 1990, and it is becoming more and more comprehensive<sup>1,5</sup>

There are several types of lasers, which have light interaction and affinity with the target tissues, producing specific effects<sup>1,2,4-6</sup>. Diode, argon, erbium, carbon dioxide (CO<sub>2</sub>) and neodymium lasers have a high affinity for water and hemoglobin and are used in incisions.

Surgical procedures such as frenectomy, gingivoplasty, gingivectomy, clinical crown augmentation and ulectomy are indicated. The decontamination of the treated region is promoted by these high-power lasers<sup>2,4-6,10,11</sup>. Depending on the clinical indication, they can be used in focused or unfocused mode. In focused mode, the greater depth and smaller diameter promoted by the action of light determines the cutting function. In the unfocused mode, the interaction of the light with the most superficial layers of the tissues provides the ablation or vaporization of tissues, frequently used in the removal of white lesions such as leukoplakia, hyperkeratosis or in the removal of carious tissue<sup>11</sup>.

Semiconductor diode lasers - gallium arsenide (GaAs) and gallium-aluminium arsenide (GaAlAs) - used in soft tissue surgery have several advantages. They are portable, compact, low cost, efficient and reliable surgical units. They have a wavelength between 810 and 980 nm<sup>1,5,6</sup>. They are absorbed by haemoglobin and melanin and have little absorption in hard tissues, providing selective action and allowing precise cuts, coagulation and vaporisation of areas around dental structures, without causing damage to dental tissues<sup>1,7</sup>. They reduce the need for anaesthesia, controlling bleeding and do not require sutures<sup>5,7</sup>. Compared to other types of lasers, diode lasers have been widely used in dental clinics<sup>1</sup>.

The purpose of this article is to present a case of lingual frenectomy using the diode laser in a 60-days-old infant.

## Case Report

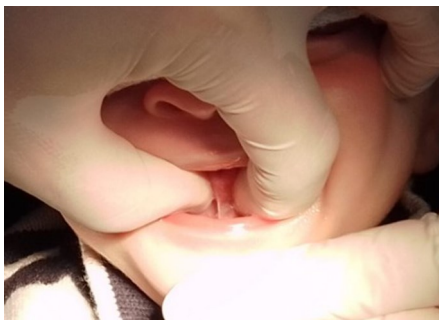
A Caucasian male 60-days-old infant, brought by his mother, attended the clinic of the School of Dentistry of the Universidade Brasil, with an indication for lingual frenectomy.

Clinically, the patient presented a persistent lingual frenum with insertion associated with ankyloglossia (Figure 1).

The indication of lingual frenectomy was requested by the pediatrician, since the lingual frenum prevented the milking movement performed during breastfeeding. Difficulty in breastfeeding was reported by the mother. No systemic alterations were reported.

Being a 60 day old baby, and because of the benefits provided, the use of surgical laser was recommended. After the doubts and clarifications were elucidated, the mother agreed with the recommendation and signed the consent form for the treatment to be performed.

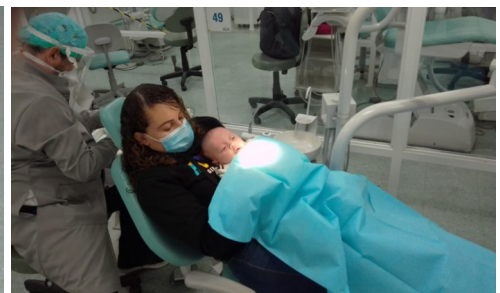The topical anesthetic was applied bilaterally adjacent to the lingual frenum. The laser used was a semiconductor diode laser (Thera Lase Surgery®, DMC, São Carlos, Brazil; P = 1.2 W;  $\lambda$  = 980 nm) (Figure 2). The care protocol followed the technical specifications recommended by the manufacturer. The mother, operator and assistant used protective eyewear (green). The baby was treated lying down and immobilized on the mother (Figures 3 and 4). A surgical field was used over the eyes of the infant for protection (Figure 5). Additionally, biosafety precautions were followed.



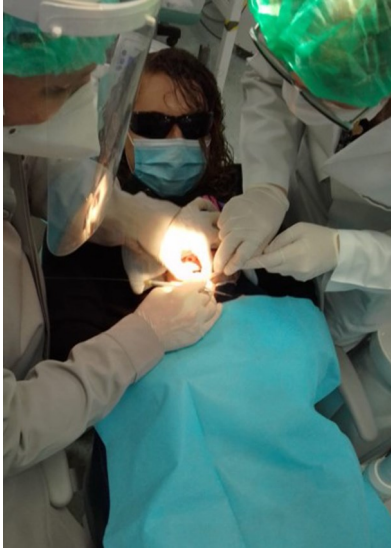
**Figure 1:** Persistent lingual frenum associated with ankyloglossia in a 60-days-old infant.



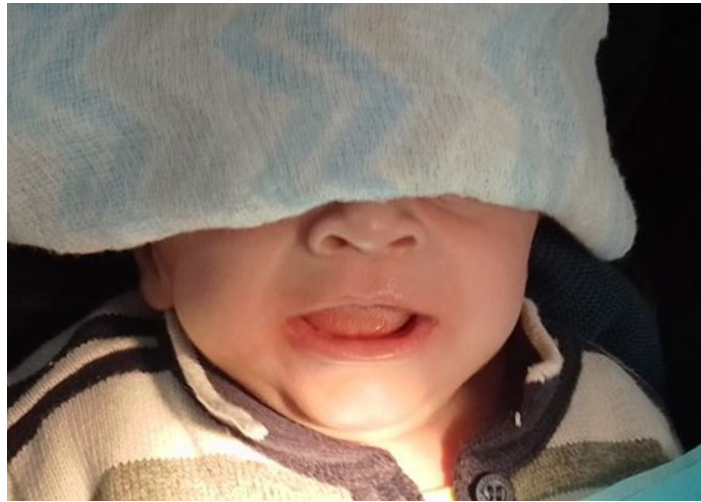
**Figure 2:** Diode laser (Thera Lase Surgery®, DMC, São Carlos, Brazil).



**Figure 3:** Infant was treated lying down and immobilized on the mother.



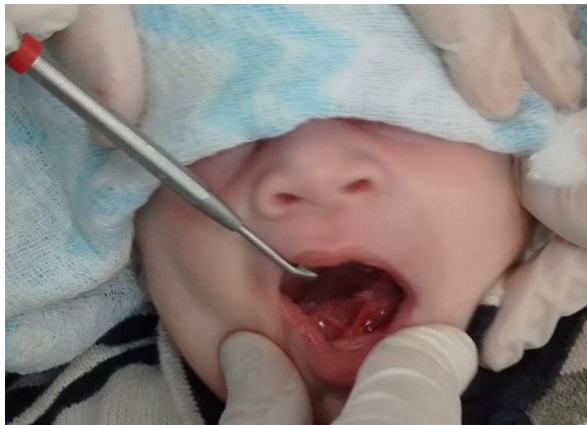**Figure 4:** Biosafety precautions inherent to the laser use were followed.



**Figure 5:** Surgical field was used over the eyes of the infant for protection.

Controlled movements were performed adjacent to the lingual frenum on the oral floor (lingual belly). Immediately after removal of the lingual frenum, the greatest amplitude of lingual movement was observed (Figure 6). Analgesic was prescribed in the post-surgical period, if necessary.

After 30 days, repair of the region was observed, as well as a greater lingual movement. No complaints or complications were reported by the mother (Figure 7).



**Figure 6:** Postoperative immediate after laser frenectomy: greatest amplitude of lingual movement was observed.



**Figure 7:** Postoperative (after 30 days): repair of the region and greater lingual movement were observed.

## Discussion

The laser diode has been widely used in several surgeries. Clinical crown augmentation surgery; biopsies; frenectomy, gingivoplasty; ulectomy; implant reopening and access; incision for draining oral abscesses; and in decontamination of the periodontal pocket<sup>7,12,13,14</sup>.

The surgical laser presents the functions of cutting, vaporization, coagulation and sterilization of the surgical site. Compared to conventional techniques, it presents several advantages and benefits.

Ease of use and reduction of surgical time are essential factors. Additionally, there is a reduction in local trauma; blockage of small blood vessels in the incision line and subsequent coagulation, favoring hemostasis; reduction of post-surgical symptomatology; reduction of anxiety before the apprehension of patients; promotion of local decontamination by the thermal effect; elimination of the need for sutures; reduction of trans- and post-surgical infections; reduction of the amount of local anesthesia and in some cases, the procedures can be performed with the use of topical anesthetic only<sup>5,9,14</sup>, as presented by us. A reduction in the need for anesthesia in 55% of soft tissue surgeries performed with high-power laser has been reported<sup>4-6,14</sup>.

Particularly in surgeries on infant patients, the use of surgical laser presented, besides the aforementioned benefits, the speed and efficacy, in the reduction of stress and trauma to the patient<sup>4-6,13,15</sup>.

Frenectomy performed with surgical laser has been widely reported. Post-surgical symptomatology reduction is widely observed, ranging from 68% to 100% of patients<sup>4,13,16</sup>.

An improvement in phonation (89%), solid alimentation (83%) and sleep (83%) was reported after the lingual frenectomy performed with a CO<sub>2</sub> laser in 37 children with a mean age of 4.2 years<sup>2</sup>. Additionally, other studies have related the performance of laser frenectomy with the improvement of obstructive sleep apnea syndrome<sup>3</sup> and the improvement of body posture, by temporomandibular dynamics and the anteroposterior flexion of the scapulas (shoulders) in the sagittal plane<sup>17</sup>.

After incision with the surgical laser, small-caliber blood and lymphatic vessels are sealed by the thermal effect, promoting the reduction or elimination of bleeding and subsequent postoperative edema. Histologically, carbonized epithelial and connective tissues can be observed, as well as occluded vessels. Subsequently, the repair process is initiated by the formation of a sero-fibrinous clot (rich in fibronectin) over the site. This clot helps to protect the wound against bacterial or mechanical frictional action. Clinically, between 48 and 72 hours after surgery, the superficial wound is hydrated by saliva, promoting its disintegration and subsequent formation of a new epithelized tissue<sup>14</sup>.

## Conclusions

The diode laser can be used as a satisfactory alternative for the execution of lingual frenectomy, particularly in infant patients, providing better trans- and post-surgical conditions. It is up to the dental surgeon, even without the indication of other health professionals, to track possible restrictions or limitations of tongue movements.

## References

1. Lima SRSM, Baptista A, Kubo H, Shitsuka C, Pedron IG. Diode laser lingual frenectomy in pediatric dentistry: case report. SAODS 2021;4(1):29-33.
2. Baxter R, Merkel-Walsh R, Baxter BS, Lashley A, Rendell NR. Functional improvements of speech, feeding, and sleep after lingual frenectomy tongue-tie release: a prospective cohort study. Clin Pediatr (Phila) 2020;59(9-10):885-892.
3. Fioravanti M, Zara F, Voza I, Polimeni A, Sfasciotti GL. The efficacy of lingual laser frenectomy in Pediatric OSAS: a randomized double-blinded and controlled clinical study. Int J Environ Res Public Health 2021;18(11):6112.
4. Tancredi S, De Angelis P, Marra M, Lopez MA, Manicone PF, Passarelli PC, Romeo A, Grassi R, D'Addona A. Clinical comparison of diode laser assisted "v-shape frenectomy" and conventional surgical method as treatment of ankyloglossia. Healthcare (Basel) 2022;10(1):89.
5. Mazzoni A, Navarro RS, Fernandes KPS, Horliana ACRT, Mesquita-Ferrari RA, Motta PB, Silva T, Gomes AO, Martimbianco ALC, Sobral APT, Santos EM, Motta LJ, Bussadori SK. BMJ Open 2021;11(11):e050733.
6. Mezzapesa PP, Lepore G, Acella V, De Giglio N, Favia G. Clinical outcomes of diode laser treatment of ankyloglossia in children and Young adults: a report of two cases. Cureus 2020;12(3):e7367.
7. Derikvand N, Chinipardaz Z, Ghasemi S, Chiniforush N. The Versatility of 980 nm diode laser in Dentistry: A case series. J Lasers Med Sci 2016;7(3):205-208.
8. Komori S, Matsumoto K, Matsuo K, Suzuki H, Komori T. Clinical study of laser treatment for frenectomy of pediatric patients. Int J Clin Pediatr Dent 2017;10(3):272-277.
9. Kafas P, Stavrianos C, Jerjes W, Upile T, Vourvachis M, Theodoridis M, Stavrianou I. Upper-lip laser frenectomy without infiltrated anaesthesia in a paediatric patient: a case report. Cases J 2009;2:7138.
10. Garcez AS, Ribeiro MS Núñez SC. Laser de Baixa Potência - Princípios básicos e aplicações clínicas na Odontologia. Rio de Janeiro: Elsevier. 2012. 259p.



11. Martens LC. Laser physics and a review of laser applications in dentistry for children. *Eur J Paediatr Dent* 2011;12(2):61-67.
12. Park S. Lasers and soft tissue: 'fixed' soft tissue surgery. *Br Dent J* 2007;202:247-253.
13. Genovese WJ, Moreira LA, Bordini PJ, Zampieri MJP, Ardohain RS, Fernandes DR. Estudo comparativo clínico entre os lasers cirúrgicos Neodímio-YAP e CO2 na remoção de hemangioma e hiperplasia fibrosa inflamatória. *Rev Assoc Paul Cir Dent* 2002;56(supl.):27.
14. Pirnat S. Versatility of an 810 nm diode laser in Dentistry: An overview. *J Laser Health Acad* 2007;4.
15. Garg N, Verma S, Chadha M, Rastogi P. Use of carbon dioxide laser in oral soft tissue procedures. *Natl J Maxillofac Surg* 2015;6(1):84-88.
16. Ortega-Concepción D, Cano-Durán JA, Peña-Cardelles JF, Paredes-Rodríguez VM, González-Serrano J, López-Quiles J. The application of diode laser in the treatment of oral soft tissues lesions. A literature review. *J Clin Exp Dent* 2017;9(7):e925-e928.
17. Saccomanno S, Pirino A, Bianco G, Paskay LC, Mastrapasqua R, Scoppa F. Does a short lingual frenulum affect body posture? Assessment of posture in the sagittal plane before and after laser frenulotomy: a pilot study. *J Biol Regul Homeost Agents* 2021;35(3 Suppl. 1):185-195.

**Citation:** Nascimento AS, Di Francesco ERS, Navarro RS, Baptista A, Pedron IG. "Lingual Frenectomy in a 60-days-old Infant: Case Report Using Diode Laser". *SVOA Dentistry* 2022, 3:3, 143-147.

**Copyright:** © 2022 All rights reserved by Pedron IG., et al. This is an open access article distributed under the Creative Commons Attribution License, which permits unrestricted use, distribution, and reproduction in any medium, provided the original work is properly cited.